Case	(121) Ureteral sciatic hernia
Authors	M. Manrique-zegarra, B. García-moreno, M. Sánchez-alegre.
Centre	Hospital General Universitario Gregorio Marañón.

CASE PRESENTATION

An 80-year-old woman presented to the emergency department referring intense left flank pain in the last 24 hours associated with nausea, vomiting and lower urinary tract symptoms without fever. Her blood tests revealed elevated inflammatory markers while urea and creatinine were normal.

Computed tomography (CT) showed moderate left hydronephrosis and a dilated ureter to the level of the left sciatic foramen, in which the ureter herniates, observing an abrupt change in caliber and a collapsed distal ureter.

There was a small amount of perinephric fluid and a delayed nephrogram of the left kidney. A double-J catheter was inserted, providing rigidity to the ureter and reducing the hernia, with improvement in her pain.

DISCUSSION

The sacrospinus ligament divides the sciatic notch into greater and lesser sciatic foramina. The piriformis muscle subdivides the greater sciatic foramen into suprapiriformis and infrapiriormis compartments.

The ureterosciatic hernia is the rarest form of sciatic hernia and it usually occurs when the ureter protrudes through the suprapiriformis compartment of the greater sciatic foramen. There are less than thirty published reports. It is usually the result of piriformis muscle weakening caused by conditions that increase intraabdominal pressure, neuromuscular or hip diseases, or congenital or acquired pelvic fascia defects.

They are more common in women aged 40 to 60, due to a wider pelvic bone and a bigger greater sciatic foramen (1). The left ureter is more often affected (2). Clinical presentation is variable depending on the size, location and herniated contents. It can present as a palpable mass with pressure and flank pain, and in severe cases with hydronephrosis, renal colic or urinary sepsis (1,2). Imaging is fundamental to establish the diagnosis.

Urography and CT are the most useful imaging modalities. In contrast-enhanced CT, the visualization of a ureteral segment posterior and lateral to the ischial spine confirms the diagnosis and allow evaluation of neighbouring structures, especially the arteries (2).

CONCLUSION

Even though a sciatic ureteral hernia is extremely rare and lacks on discerning symptomatology, it is important to recognize its unique imaging features and keep it in mind in a patient with renal colic and obstructive uropathy.

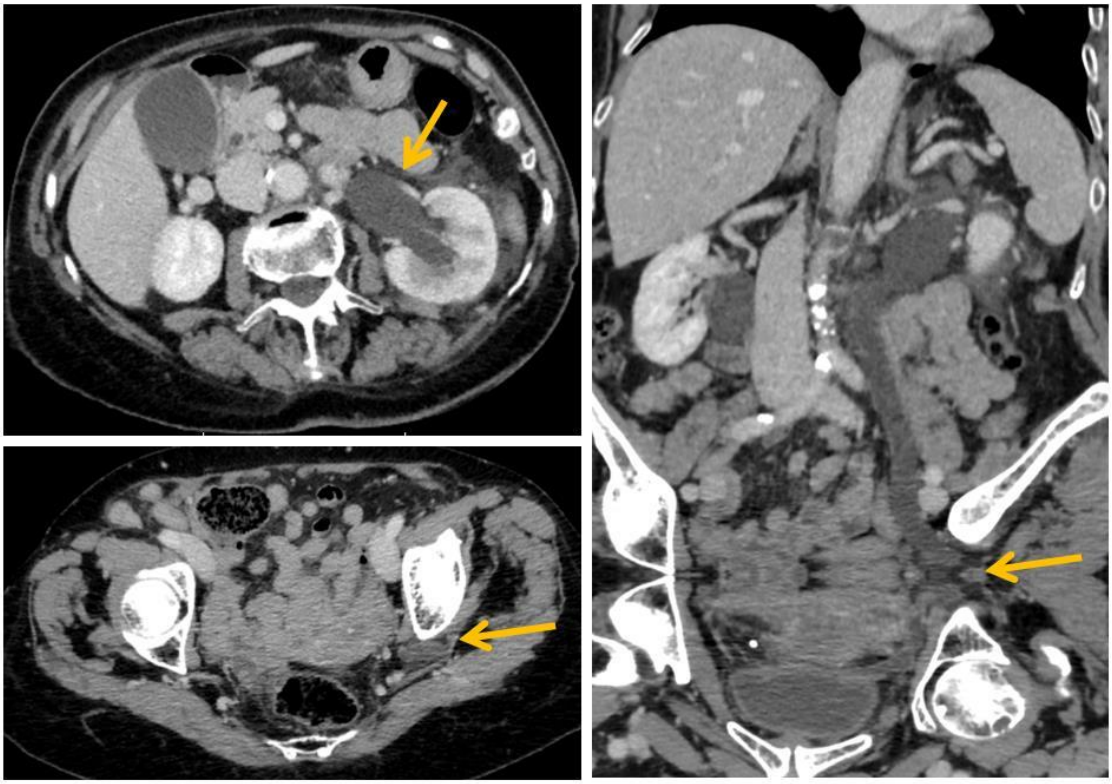

Moderate left hydronephrosis and a dilated ureter to the level of the left sciatic foramen

BIBLIOGRAPHY

- Gandhi J, Yea-Leea M, Joshid G, Smithe NL, Ali-Khana S. Ureterosciatic hernia: An up-to-date overview of evaluation and management. Translational Research in Anatomy 2018;11: 5-9.

- Loffroy R, Bry J, Guiu B, Dubruille T, Michel F, Cercueil JP, et al. Ureterosciatic Hernia: A Rare Cause of Ureteral Obstruction Visualized by Multislice Helical Computed Tomography. Urology 2007; 69: 385.e1–385.e3.