Case	(227) Capitellum fracture disappeared in initial study
Authors	M. Sánchez-robles, M. Cegarra-navarro, E. Alias-carrascosa, I. Morales-González, A. Lanagran-torres, J. Soler-gutiérrez.
Centre	Hug. Reina Sofía. Murcia.

CASE PRESENTATION

A 44 year-old male who goes to the emergency room for pain and functional limitation in his right elbow after suffering a fallen with his arm extended. On examination, he presented functional impotence for the pronation-supination and pain on palpation in the radial head and joint effusion.

Plain radiographs of the right elbow showed only radial head fracture, however, radiological control showed a displaced capitellum fracture. The study was completed with CT scans to assess the type of fracture and degree of displacement of fragments.

DISCUSSION

Capitellum fractures are rare and only affect the articular portion of the lateral condyle. Bryan e Morrey (1985) classified capitellum fractures into three types and later Mckee added a fourth type of fracture (1996): type I (Hanh Steinthal): affects a large portion of the humeral condyle; type II (Kocher Lorenz): only affects the cartilage of the condyle with very little subchondral bone; type III (Broberg-Morre): comminuted fracture; Type IV (McKee): fragment of greater dimensions of capitellum and troclea (1).

The CT assesses more precisely the extent of the fracture and number and displacement of fragments. Radiologist must know this type of fractures, classify them appropriately and provide in the report the findings that the orthopedic surgeon needs to know for surgical planning. The treatment of these fractures will depend on their displacement (1, 2).

The undisplaced fractures are immobilized and the displaced fractures are operated (type I and some type II: synthesized with screws; type II and III: the fragments are removed).

CONCLUSION

Our patient presented a type II capitellum fracture associated with a radial head fracture. The first imaging technique is radiography, but in this type of fracture, CT should be performed to plan surgical treatment.

The treatment performed was open reduction and internal fixation of the radial head fracture with screws and fixation the osteochondral fragment of the capitellum with screws. The patient evolution favorably.

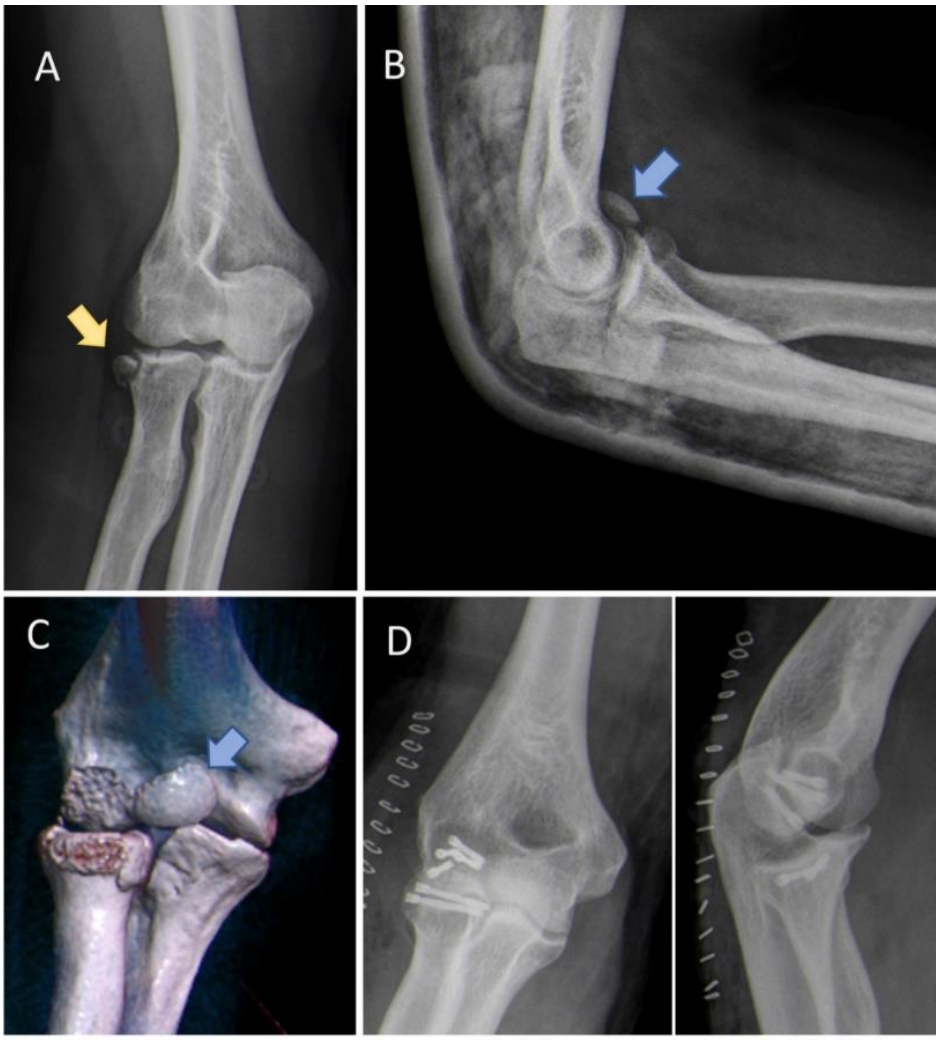

Anteroposterior radiograph of the elbow (a) showing the radial head fracture (yellow arrow). Lateral radiograph of the elbow (b) showing the capitellum fracture (blue arrow). CT scan and 3D reconstruction CT (c)scan showing displacement capitellum fracture (blue arrow). Post-surgical radiological control (d).

BIBLIOGRAPHY

- Guitton TG, Doornberg JN, Raaymakers E, Ring D, Kloen P. Fractures of the capitellum and trochlea. J Bone Joint Surg Am. 2009; 91: 390-7.

- Pal Singh A, Pal Singh A, Vaishya R, Jain A, Gulati D. Fractures of capitellum: a review of 14 cases treated by open reduction and internal fixation with Herbert screws. Int Orthop. 2010; 34: 897-901.