Case	(286) Tracheal rupture after endotracheal intubation
Authors	C. Marichal Hernández, M. Fernández Del Castillo Ascanio, S. Benítez Rivero, S. Duque Fernández De Vega, Y. El Khatib Ghzal, V. Pantoja Ortiz.
Centre	Hospital Universitario Nuestra Señora De Candelaria.

CASE PRESENTATION

A 36-year-old woman admitted to the ICU due to severe bilateral pneumonia with respiratory failure. After endotracheal intubation, the patient suffered subcutaneous emphysema and a bilateral pneumothorax, that was difficult to reexpand with bilateral chest tube.

The first image corresponds to an x-ray, where there are extensive areas of bilateral consolidation. The second image was obteined a few hours after intubation and shows a bilateral pneumothorax, with pneumomediastinum and severe subcutaneous emphysema.

The last two images correspond to a contrast-enhanced CT scan, where we can see an injury of the posterior tracheal wall due to the rupture of the pars membranosa, adjacent to the tube tip.

DISCUSSION

Tracheal rupture is a rare condition, and its most common cause is trauma. Iatrogenic rupture is an unfrequent entity with many etiologies (intubation, tracheostomy, bronchoscopy, placement of stents, esophagectomy, and others), although orotracheal intubation is the most common cause. Its relevance derives from the high associated morbidity and mortality.

The incidence estimation ranges from 0.05% to 0.37% of all orotracheal intubations performed. It is more prevalent in women and patients older than 50 years. A multi-factorial origin of rupture has been proposed, with important roles for mechanical (trauma during intubation, overinflation of the cuff and vigorous coughing...), anatomical, and individual factors, many of them still undefined. Tracheal lacerations are usually vertical and longitudinal and located at the junction of the cartilaginous and membranous portions of the trachea.

Diagnosis is based on a high clinical suspicion, thanks to the appearance of clinical signs and symptoms that, although not specific, are highly suggestive: subcutaneous emphysema, respiratory insufficiency, pneumothorax, and hemoptysis.

CT may help identify the site of tracheal laceration in 70%–100% of cases. If CT findings suggest an injury to the trachea, definitive diagnosis with bronchoscopy should be attempted to confirm the diagnosis and to evaluate the site and extent of injury.

CONCLUSION

Tracheal rupture is a rare but serious complication that may occur after endotracheal intubation. It usually presents as a linear lesion in the membranous wall of the trachea. CT may help identify subcutaneous emphysema, pneumothorax and the site of tracheal laceration.

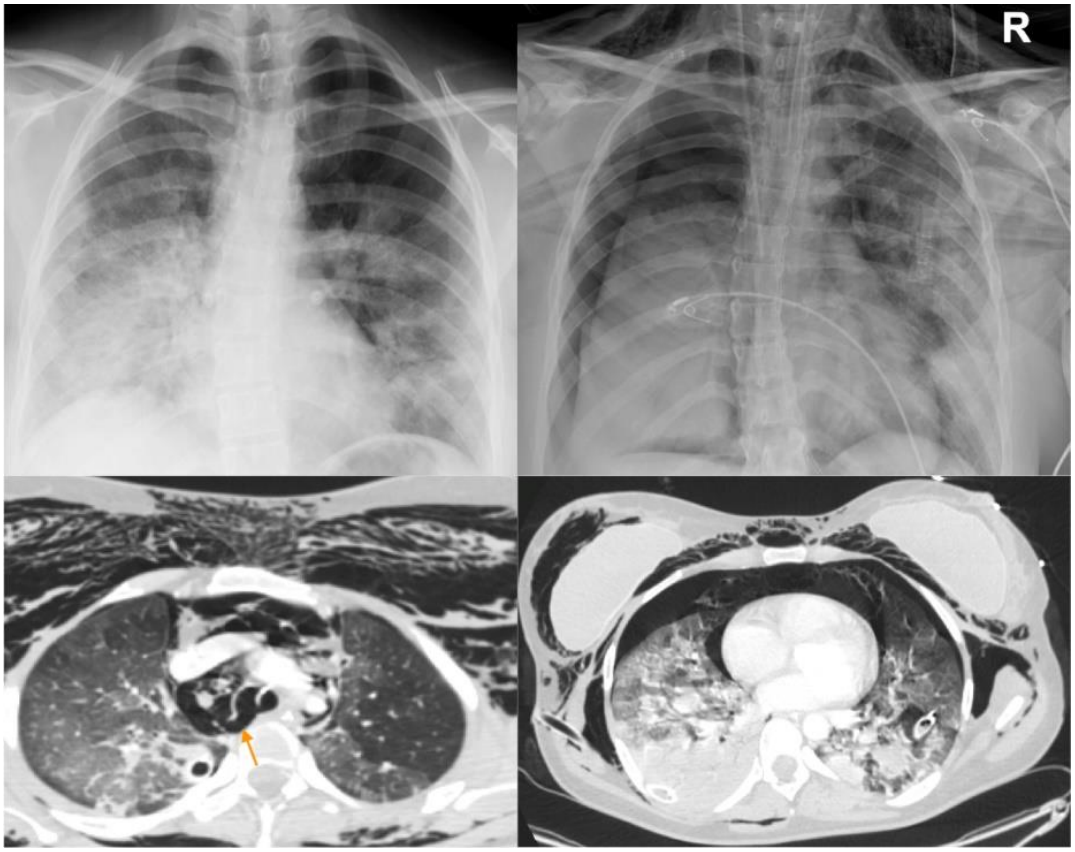

BIBLIOGRAPHY

- Chen JD, Shanmuganathan K, Mirvis SE, Killeen KL, Dutton RP. Using CT to diagnose tracheal rupture. American Journal of Roentgenology. 2001;176(5):1273–1280.

- Kaewlai R, Avery LL, Asrani AV, Novelline RA. Multidetector CT of blunt thoracic trauma. Radiographics. 2008;28:1555–1570