Case	(376) Ankylosing spondylitis. a risk factor for both, spine fracture and aorta rupture?
Authors	A. Marin Toribio I. Navas Fernández-silgado, V. González Méndez, E. Aguirre Pascual, M. Castaño Reyero, J. Arevalo Perez.
Centre	12 Octubre Hospital; Memorial Sloan Kettering Cancer Center.

CASE PRESENTATION

A 56-year-old man crashed pedestrian was transferred to our hospital emergency department. On arrival, he was in a hypovolemic shock condition and required massive transfusion and administration of vasoactive drugs. After a negative FAST exam, a thoracoabdominal CT scan was immediately performed. We found an infrarenal aortic rupture and a large retroperitoneal hematoma with active bleeding reaching the intervertebral space.

Besides, a sagittal MPR image showed a hyperextension lumbar spine injury with the line fracture through the disc space, producing a distraction of the intervertebral space. By last we found several ankylosing spondylitis (AS) findings, so traumatic abdominal aortic rupture in association with a fractured ankylosed lumbar spine segment was made.

The patient underwent surgery for aortic prosthesis placement but finally died.

DISCUSSION

A rigid spine (like in AS, diffuse idiopathic skeletal hyperostosis, degenerative spondylosis and a surgically fused spine) has biomechanical changes which predispose to serious spinal injury, even as a result of minor impact.

AS patients have a 7x increase in the incidence of spinal fracture compared with that of the general population. The most common mechanism of injury is hyperextension (70% of cases) and cervical spine fractures are the most frequent although thoracic or lumbar spine can also occur.

On the other hand although unfrequent is better known the rupture of aorta caused by a flexiondistraction forces (often in the setting of a seatbelt trauma or a fall), with aortic injury due to displacement of a spine segment. In our case, vascular complications in the setting of fractured ankylosed spine are rare but we can find a disruption, pseudoaneurism or dissection of aorta, or even a caval vein rupture.

They probably happen as the result of inflamatory changes in AS, which cause the aorta adventitia to become firmly adherent to the anterior longitudinal ligament. So when the anterior column is fractured and distracted due to hyperextension forces, aorta can be also injured. MDCT and MPR reconstructions are very useful in the diagnosis but we must be aware rigid spine is a risk factor for both aortic and spine lesion.

CONCLUSION

Radiologist must be aware that rigid spine is a risk factor for spine fracture (even in minor traumas). In a AS patient spine lesion can associate vascular lesion as a result of inflamatory changes, which cause the aorta adventitia to become firmly adherent to the anterior longitudinal ligament.

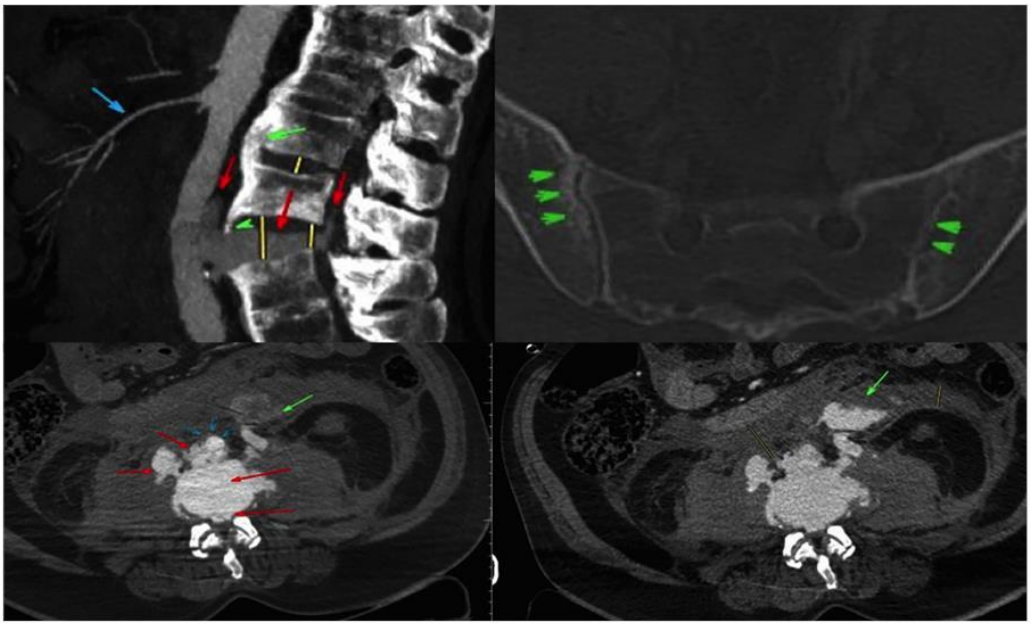

A. Sagittal MIP image in arterial phase MDCT. B. Axial image to show sacroiliac joints. C and D: Axial images in arterial (C) and portal (D) phases. A. shows a hyperextension lumbar spine injury with the line fracture through the disc space, producing a distraction of the intervertebral space. C and D: Aortic rupture with a large retroperitoneal hematoma with active bleeding (green arrows) in retroperitoneum reaching the intervertebral and anterior epidural spaces (red arrows). A and B: Signs of ankylosing spondylitis (green arrows in A a B).

BIBLIOGRAPHY

- Savolaine E.R., Ebraheim N.A., Stitgen S., et al.: Aortic rupture complicating a fracture of an anky- losed thoracic spine: a case report. Clin Orthop Relat Res, 1991, 272: 136-140

- Shah NG, Keraliya A, Nunez DB, Schoenfeld A, Harris MB, Bono CM, et al. Injuries to the Rigid Spine: What the Spine Surgeon Wants to Know. Radiographics. 2019 Apr;39(2):449–66