Case	(481) Stealthy posterior circulation stroke sintomatology and the use of ct neuroperfusion in the emergency room.
Authors	F. García Gutiérrez, M. Román Sastre. F.j. García Gutiérrez, Móstoles, Spain. M.m. Román Sastre, Mósto
Centre	Hospital Universitario De Móstoles.

CASE PRESENTATION

We present the case of a 70 year old man who came to the emergency room with dizziness and ataxia. On examination the patient showed a right facial palsy, initial left hemiplegia that reverted, nystagmus and diplopia.

We performed a non-enhanced head CT, which revealed areas of low attenuation in left cerebellar hemisphere and in the right occipital lobe, with corticosubcortical involvement. In addition, hyperdensity of the first segment of the basilar artery was observed.

An CT Neuroperfusion displayed a delayed time to peak in the entire posterior circulation, with cerebral blood flow falling in the right cerebellar hemisphere.

An Angio-CT confirmed a defect of repletion of the basilar artery. A mechanical thrombectomy with complete opening of the basilar artery was carried out in another institution.

DISCUSSION

Occlusions of the posterior circulation arteries are related to a fifth of all strokes, and basilar artery occlusion is rare (~1% of all strokes). Patients will present with sudden and dramatic neurological impairment:

1. Sudden death/loss of consciousness.

2. Top of the basilar syndrome: visual and oculomotor deficits, behavioral abnormalities, somnolence, hallucinations and dream-like behavior, motor dysfunction is often absent.

3. Proximal and mid portions of the basilar artery (pons) can result in patients being 'locked in': complete loss of movement (quadriparesis and lower cranial dysfunction), preserved consciousness, preserved ocular movements (often only vertical gaze).

It can be due to either thromboembolism, atherosclerosis or propagation of intracranial dissection. Usually midsegment involvement implies atherosclerosis with thrombosis (which was our case).

Diagnosis can be made via Cerebral angiography, Transcranial Doppler, non-contrast CT plus multimodal CT imaging and MRI.

As with any acute stroke, a non-enhanced head CT should be performed promptly; the hyperdense basilar artery sign, may be the only finding in an acute presentation. However a CT Neuroperfusion can be critical for diagnosis when the sintomatology is insidious and can complement the radiological findings of Non enhaced CT and AngioCT.

CONCLUSION

Awareness of the clinical features suggestive of a posterior circulation stroke and recognition of the hyperdense basilar artery sign on non-contrast CT, with rapid confirmation of the diagnosis via multimodal CT (CT Neuroperfusion, with the caracteristics pattern) or MRI (when available) and initiation of intravenous or intraarterial thrombolysis with rapid Neurointerventional consultation, will decrease the high mortality and morbidity associated with this devastating condition.

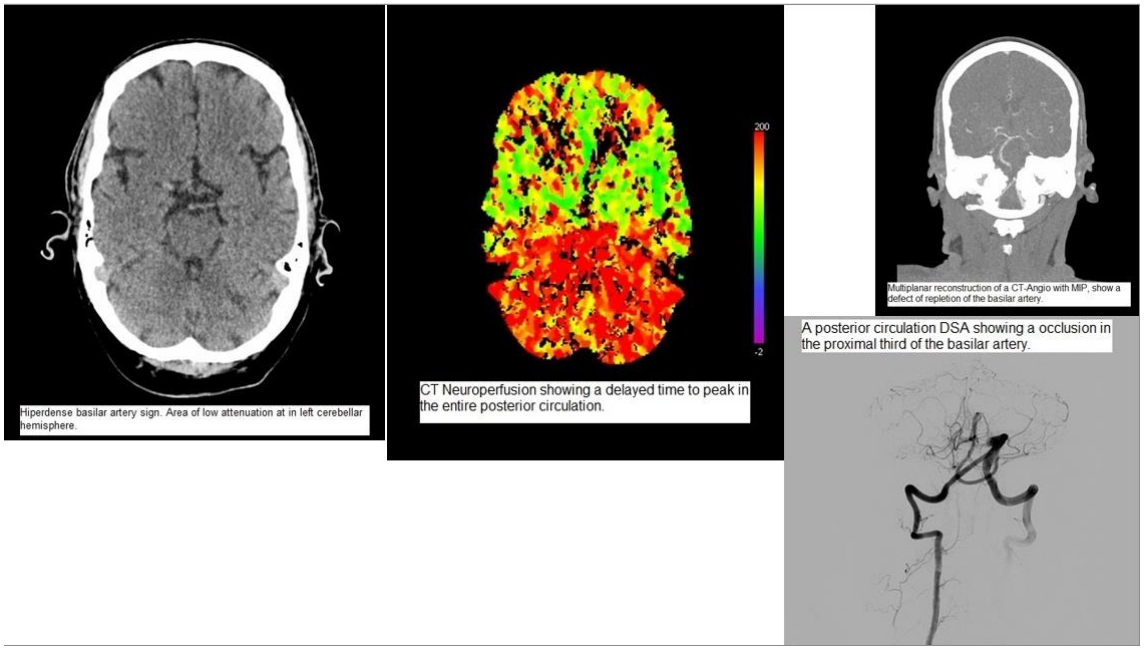

BIBLIOGRAPHY

- Goldmakher GV, Camargo EC, Furie KL et-al. Hyperdense basilar artery sign on unenhanced CT predicts thrombus and outcome in acute posterior circulation stroke. Stroke. 2009;40 (1): 134-9.

- de Lucas EM, Sánchez E, Gutiérrez A et-al. CT protocol for acute stroke: tips and tricks for general radiologists. Radiographics. 2008;28 (6): 1673-87.