Case	(511) Atypical presentation of acute appendicitis in childhood
Authors	I. Vicente Zapata1, B. Gholipour2, M. Easty2, A. Calder2.
Centre	1general University Hospital Morales Meseguer; 2great Ormond Street Hospital.

CASE PRESENTATION

13 year old girl with learning difficulties, was admitted under Orthopaedics, having presented with signs of sepsis and progressive painful swelling of the right thigh. Abscess/fasciitis were suspected on ultrasound and an extended contrast-enhanced abdominal CT was performed to help identify the source.

CT showed a large right-sided retroperitoneal collection, with extensive gas locules, extending along the iliopsoas muscle, from diaphragmatic level down to midthigh and even posteriorly through an abdominal wall defect. Furthermore, two small calcific foci (likely appendicoliths) were seen within the retroperitoneal collection.

Laparotomy confirmed a diagnosis of perforated retroperitoneal appendix. Two weeks later, she underwent a CTPA and V/Q scan secondary to respiratory failure which demonstrated bilateral pulmonary emboli and globally reduced perfusion in the right lung. The patient remains in intensive care, months after presentation.

DISCUSSION

The clinical diagnosis of acute appendicitis can be challenging as approximately one-third of children with the condition have atypical clinical findings [1].

The delayed diagnosis of this condition is associated with serious complications. Perforation being one of the most severe complications, is associated with further complications in up to 50% [2] as well as a high morbidity and mortality rate, ranging from 23 to 73% [2] Therefore, when perforated appendicitis is suspected an abdominal CT should be considered for a prompt diagnosis and to avoid any consequent delay in management [1, 2]. Classic CT findings in perforated appendicitis are [3]:

- Abscess/Phlegmon: abscess is the most frequent complication of perforated appendicitis [4] and if it is not promptly diagnosed, infection may spread to adjacent structures and spaces, as in our case.

- Extraluminal air.

- Extraluminal appendicolith: Appendicoliths are associated with a higher probability of perforation. Therefore, the presence of extraluminal appendicoliths in the context of periappendiceal inflammation, even if the appendix is not recognisable, should be considered diagnostic of perforation [1-4].

- Defect in mural enhancement if the appendix is visible (not very often).

CONCLUSION

A high index of suspicion and familiarity with atypical presentations and their CT features are critical for the correct diagnosis of acute appendicitis in children, to avoid a delay in diagnosis that could result in life-threatening complications.

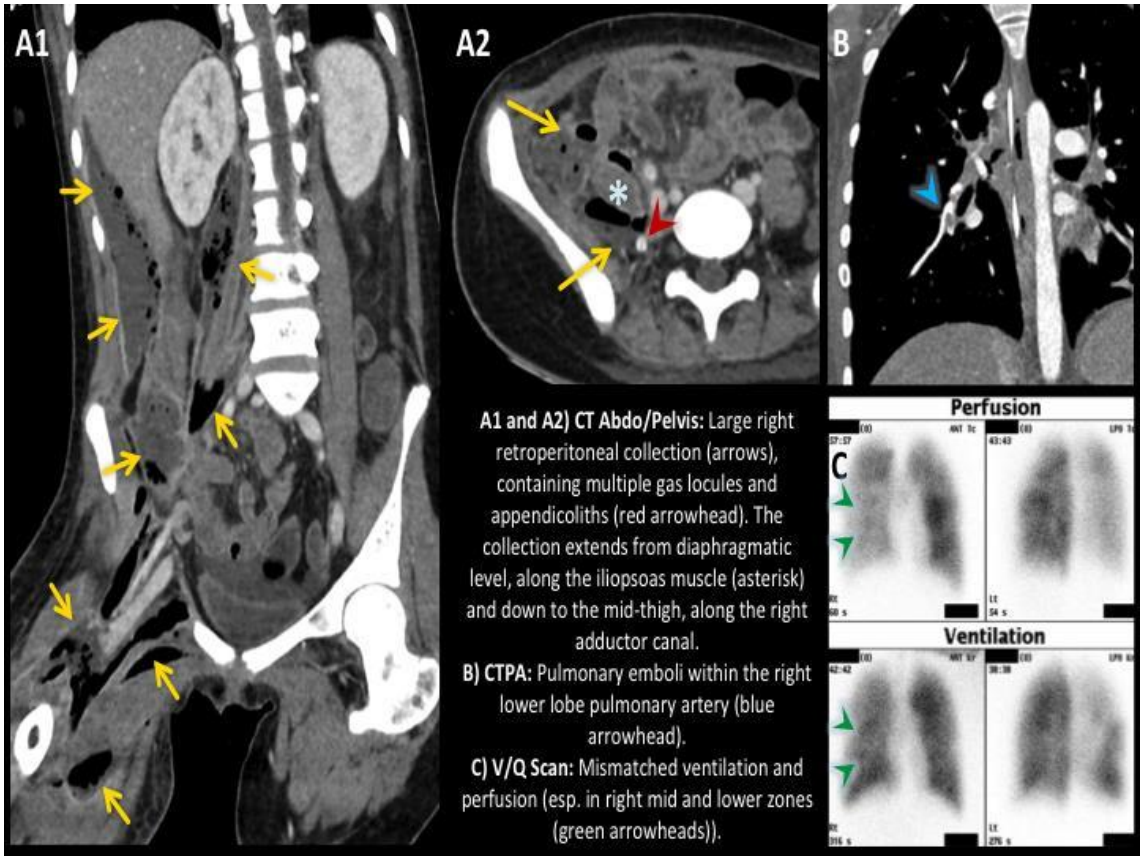

A1 and A2) CT Abdo/Pelvis: Large right retroperitoneal collection (arrows), containing multiple gas locules and appendicoliths (red arrowhead). The collection extends from diaphragmatic level, along the iliopsoas muscle (asterisk) and down to the mid-thigh, along the right adductor canal.
B) CTPA: Pulmonary emboli within the right lower lobe pulmonary artery (blue arrowhead).
C) V/Q Scan: Mismatched ventilation and perfusion (esp. in right mid and lower zones (green arrowheads)).

BIBLIOGRAPHY

- Leite NP, Pereira JM, Cunha R, Pinto P, Sirlin C. CT Evaluation of Appendicitis and Its Complications: Imaging Techniques and Key Diagnostic Findings. AJR 2005; 185: 406–417.

- Sivit KJ, Siegel MJ, Applegate KE, Newman KD. When Appendicitis Is Suspected in Children. Radiographics 2001; 21: 247–262.

- Horrow MM, White DS, Horrow JC. Differentiation of perforated from nonperforated appendicitis at CT. Radiology 2003; 227: 46–51.

- Chin CM, Lim KL. Appendicitis: Atypical and Challenging CT Appearances. Radiographics 2015; 35: 123–4.