Case	(557) Subarachnoid fat after sacral trauma
Authors	A. Sánchez García, L. Alonso Irigaray, E. Diez Lasheras, R. Gonzalez Serrano, A. Valero Macia, D. Quintana Blanco.
Centre	Hospital Universitario De Álava.

CASE PRESENTATION

We present the case of an 84 year-old male precipitated from a first floor. Body-CT is performed according to the protocol of the University Hospital of Alava: Cranium and neck in 2 ranges without intravenous contrast + thorax -abdomen and pelvis 70 seconds after the administration of 100 ml of Iopamiro 300 ®:

- Brain: Without significant findings. (Figure 1)

- Torax: Left costal fractures and homolateral scapula.

- Abdomen and pelvis: Hematoma in iliac fossae and pelvis. Active bleeding from left internal iliac branch and at the insertion of the pectinium muscle and internal obturator. Pubis diastasis.

- Fractures: Bilateral transverse processes from L2 to L4, anterior body of L4, bilateral spondylolysis of L5. Sacral fracture (Figure 2) with spondylopelvic dissociation, right ischial tuberosity to isquipubian branch, posterior column of the left acteabulum and multiple fractures in the right iliac bone.

Control CT 2 days later:

New onset of left frontoparietal subdural hematoma (6 mm).

New onset of fat drops in prepontine and suprasellar cisterns. (Figure 3)

Diagnosis: Intracraneal subarachnoided fat migrated from sacral trauma.

DISCUSSION

Subarachnoid and intraventricular fat it is an uncommon finding that is usually related to the rupture of derrmoid and epidermoid tumors, either as a consequence of an spontaneus rupture or after surgical removal. Intraventricular and subarachnoid fat after trauma, in absence of intracraneal or intraspinal tumor, is an exceptional finding. (1) (2)

Fat can access to the ventricular system by retrograde migration (through the fourth ventricular outlet foramina) as a result of head position and CSF pulsation from the spine or subcutaneus tissue after trauma. (1)

CT imaging optimized for brain parenchyma fat bubbles can simulate pneumocephalus, but imaging for bone detail will easily differentiate fat from air. HU measurements show densities within the fatty range. (Figure 4)

In MRI fat bubbles are hyperintense in T1 and T2-weighted images. To differenciate it from cerebral fat embolism, this condition presents a pattern of intravascular distribution. (2)

The presence of fat in the subarachnoid and or ventricular space may induce complications: aseptic meningitis, hydrocephalus, ischemia, calcification due to meningeal inflmatory reaction, obstrution of CSF flow, irritation of vascular and neural structures. (1)

CONCLUSION

Although very rare we must remember the possibility that the presence of subarachnoid or intraventricular fat, especially in the absence of previous surgical interventions, may be secondary to spinal trauma, particulary sacral.

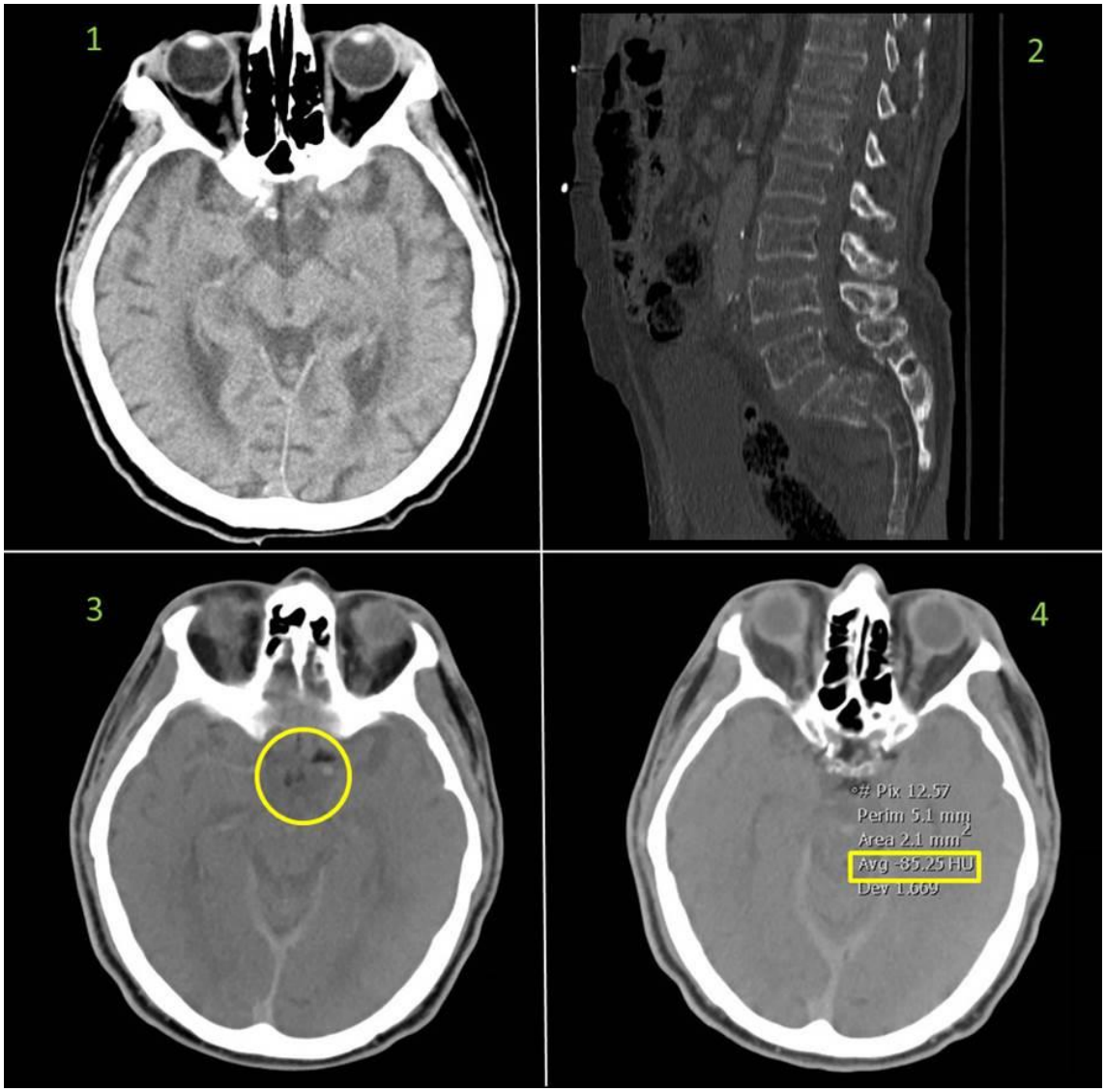

BIBLIOGRAPHY

- Lyo IU, Sim HB, Park JB and Kwon SC. Intraventricular and subarachnoid fat after spinal injury. Journal of Korean Neurosurgical Society. Soc 2008 Aug;44 (2): 95-97.

- Carreres Polo J, Álvarez Martínez MV, Sánchez Mateos D. Grasa y hemorragia en el espacio subaracnoideo intracraneal por fractura sacra con disociación espondilopélvica. Radiología 2017-11-01. Volumen 59 Num 6 Pgs 535-539.