Case	(597) The importance of lateral chest x-ray in the emergency.
Authors	L. Martínez Camblor, G. Fernández Suárez, A. Cernuda García, E. Nava Tomás, A. Prieto Fernández, M. Blanco Guindel.
Centre	Hospital Universitario Central De Asturias.

CASE PRESENTATION

A 49-year-old woman came to the emergency department for cough, chest pain and positional dyspnea. She had not fever or expectoration and the physical examination was normal. The patient was a smoker of 20 cigarettes a day and had not medical history. Chest x-ray showed both mediastinal and lung mass with tracheal compression in lateral chest x-ray. The CT confirmed the findings and the patient was hospitalized for airway control and endobronchial biopsy (EBB).

DISCUSSION

For the diagnosis of a mass that in the posteroanterior (PA) projection erases the right paratracheal band and supra-aortic trunks, multidetector computer tomography (MDCT) helps us to discern its origin in right upper lobe or anterior mediastinum.

A lung mass abutts the mediastinal surface and creates acute angles while mediastinal mass creates obtuse margins with the lung 1. In this case we observe both situations, a mass in the right upper lobe and a mediastinal mass.

There is a silhouette sign in PA with the supra-aortic trunks and we situate it in the middle mediastinum on the lateral radiograph. If we find a mass in a chest x-ray of a smoker patient, chest CT (to characterize findings) and abdominal CT (to complete studies) must be included. But should we do it urgently?.

As long as we have a mediastinal mass, we should observe the tracheal luminogram and ask for patient's clinic. In this case the mass caused an anterior compression of the tracheal wall and the patient had positional dyspnea, so an emergency chest CT was performed.

The patient did not tolerate supine decubitus and CT was made in prone position. Diagnosis of lung mass (40 x 26 mm) with well-defined margins that contacts the mediastinal pleura is identified. Metastasic adenopathic conglomerate (93 x 65 mm) that caused tracheal narrowing, superior vena cava and azygos vein infiltration was confirmed.

CONCLUSION

We can differentiate if a lesion is in the lung or in the mediastinum with the angles that the mass creates with them. The margins with the lung will be obtuse in mediastinum lesions and acute in lung lesions.

Given the finding of a mediastinal mass on a chest radiography, we can not forget to look for tracheal involvement in both projections because if we observed a tracheal compression, we have a true medical emergency.

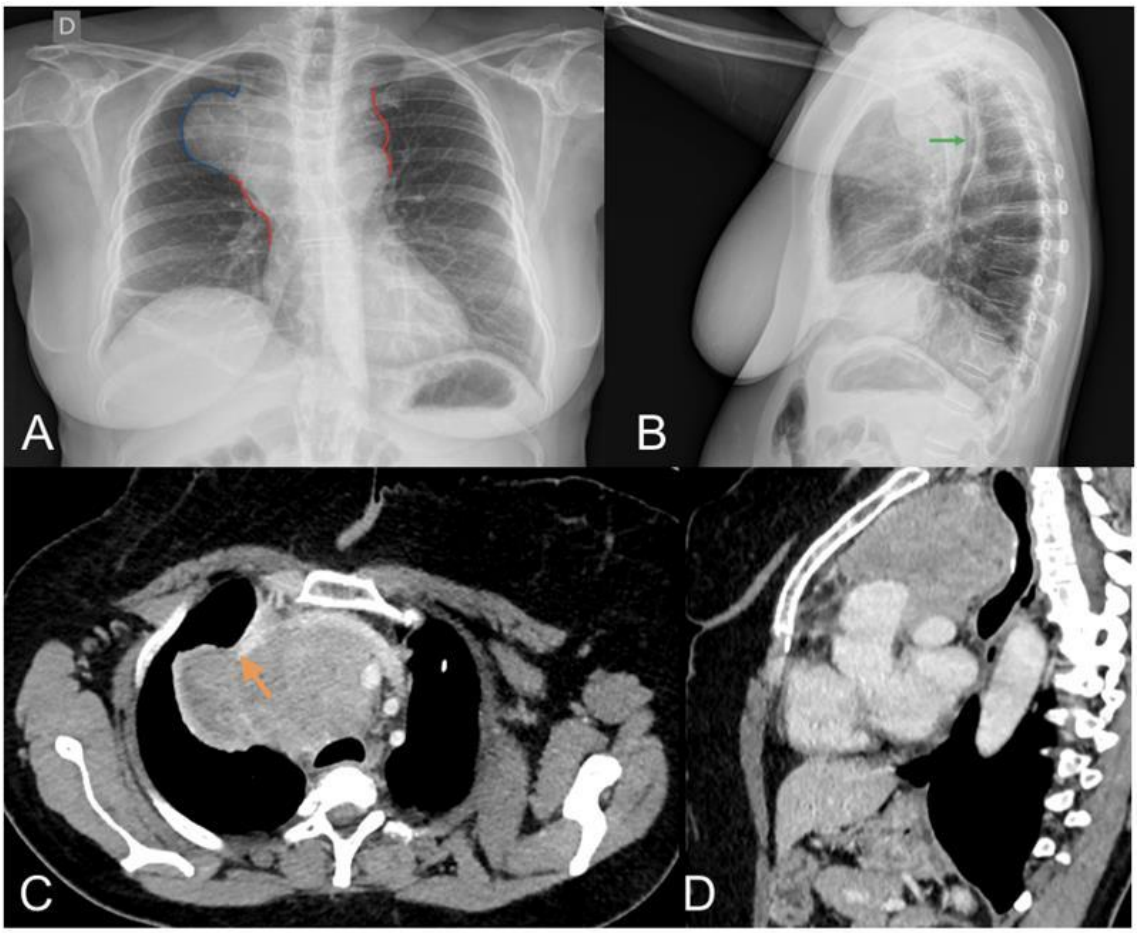

A: Chest x-ray shows acute angle of lung mass (blue) and obtuse margins of mediastinum mass (red); B: Lateral chest x-ray shows the compression of the anterior tracheal wall (green); C,D: Chest CT shows the same findings and also a superior vena cava collapse (orange).

BIBLIOGRAPHY

- Camilla R. Whitten, A Diagnostic approach to mediastinal abnormalities, May 2007 RadioGraphics, 27,657-671.

- Jerry M. Gibbs et al. Lines and Stripes: Where Did They Go? From Conventional Radiography to CT. RadioGraphics 2007;27:33-48