Case	(655) Penumbra pattern on ct perfusion; does it always imply stroke?
Authors	E. Diez Lasheras, J. Sagasta Urrutia, A. Sánchez García, I. Hernández Sastre, A. Valero Macià, G.a. Finol.
Centre	H U A

CASE PRESENTATION

This case involves an 80 year old man who was hospitalized due to a respiratory infection.

The most relevant findings in his medical history were type 2 DM, high blood pressure (HBP), dyslipidemia, former smoker, chronic renal failure and prosthetic aortic valve (anticoagulated with acenocumarol).

His symptoms started in the morning after having been talking to his room partner.

He presented with sudden slurred speech that lasted for 20-30 minutes without comprehension impairment. With the suspicion of acute ischemic stroke a cranial CT was performed, with neuro perfusion study and CT angiography. Non-enhanced CT didn't show hemorrhagic complications and ASPECTS score was 10/10.

Perfusion study showed a penumbra pattern with increased mean transit time (MTT), decreased cerebral blood flow (CBF) and preserved cerebral blood volume (CBV) affecting both the middle cerebral artery and the anterior cerebral artery territories.

On CT angiography a critical stenosis of the proximal internal carotid artery (ICA) was observed, with distally preserved flow (even though diminished compared to the contralateral flow). Angiography confirmed the irregular critical narrowing of the ICA.

DISCUSSION

Apart from acute ischemic stroke, several clinical situations may present with a penumbra pattern on CT perfusion, such as extracranial and intracranial stenosis, non acute brain ischemia, venous congestion, vascular disregulation and anatomic variants, like arterial hypoplasia/agenesia

The findings on neuro perfusion study in our case were interpreted as chronic hypoperfusion/diminished flow in the entire ICA territory secondary to the critical stenosis with a transient ischemic attack (TIA) that caused the speech impairment.

CONCLUSION

In elder patients the most common cause of penumbra pattern in neuro perfusion studies is acute ischemic stroke (thrombotic vs embolic) but there are other clinical situations that may present with this pattern such as chronic hypoperfusion secondary to extracranial stenosis of the ICA.

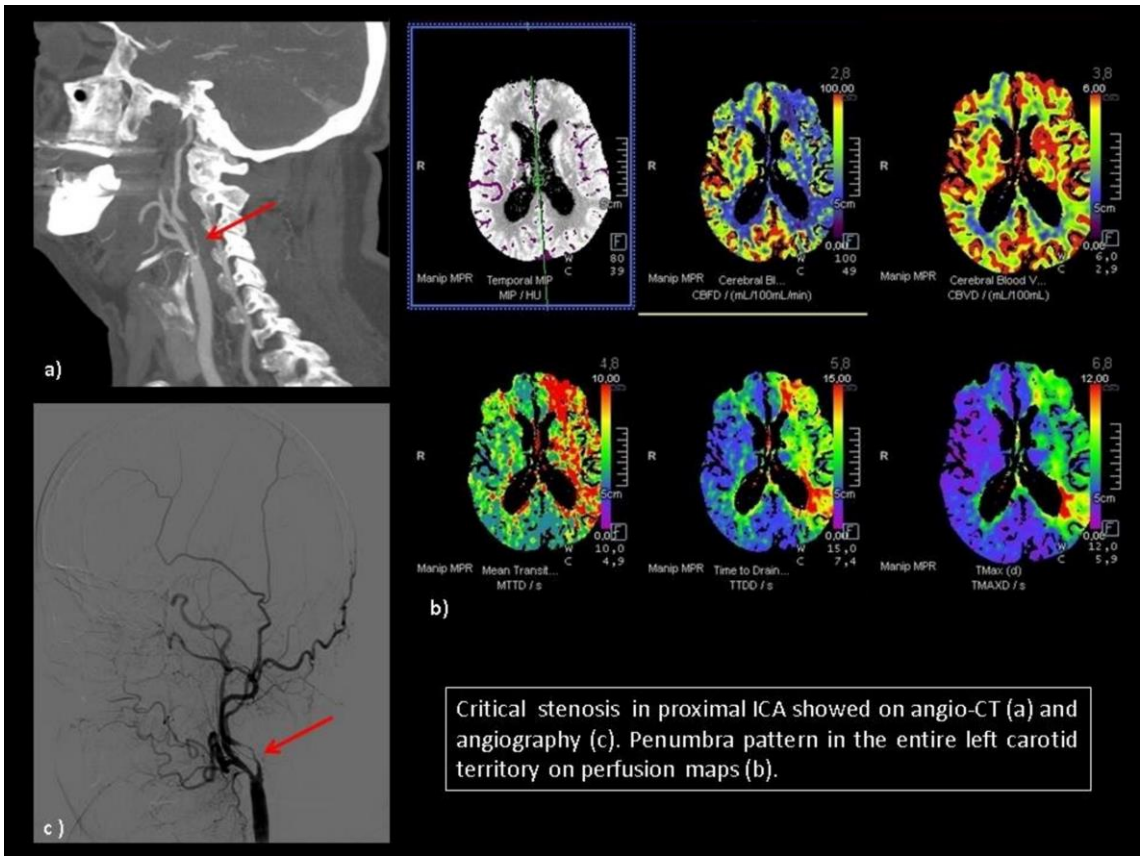

BIBLIOGRAPHY

- Vilela P. Acute stroke differential diagnosis: Stroke mimics. European Journal of Radiology 2017; 96: 133-144

- Menon BK, Goyal M. Imaging Paradigms in Acute Ischemic Stroke: A Pragmatic Evidence-based Approach. Radiology 2015;277:7-12