Case	(727) Stroke mimics in emergency department: a case report
Authors	L. Prada San Martin, B. Souto Canteli, S. Larburu Zabala, M. Salomón De La Vega, A. Dolado Llorente, J. Mendiola Arza. Osakidetza
Centre	H.u. Cruces.

CASE PRESENTATION

A 81 year old man was brought to our institution's emergency department with an episode of acute loss of consciousness and deviation of the mouth to his right. His medical history included a recent colon cancer surgery and an atrial fibrillation. Non contrast enhanced CT(NECT), perfusion CT(PTC) and CT angiography(CTA) were performed.

Non contrast enhanced TC showed a right occipital subcortical hypodensity corresponding to a chronic ischemic lesion, without evidence of hemorrage or early signs of stroke.

Prediction colour maps(Figure1) didn't manifest significant alteration in right hemisphere, whilst ischemic penumbra in left temporoparietal lobes was revealed.

However, if we notice the absolute values of PTC(Figure3), there's a decreased MTT(mean transit time) and TTP(time to peak) in the right temporopaerital lobes, an increased CBF(cerebral blood flow) and unaltered CBV(cerebral blood volume), with normal values in the left lobe.

CT angiography didn't reveal occlusion or stenosis in the circle of Willis or in carotid arteries. However, it pointed an increased vascularity in the right lobe(Figure 2).

DISCUSSION

The PTC performed to our patient revealed decreased MTT and increased CBF in the right lobe and almost normal values in the left lobe. CTA didn't show stenosis in vascular territory. Therefore, imaging wasn't consistent with acute stroke.

Approximately 5-30% of "code strokes" correspond to mimics, and imaging can be crucial to distinguish them.One of the main entities that can be indistinguishable from stroke is status epilepticus (SE).

PTC in SE traduces an increased metabolic cerebral activity shown as a decreased MTT and increased CBF, unlike acute stroke, and the affected territory usually doesn't correspond to a single vascular territory. These values could be interpretated as relatively increased MTT and decreased CBF by the software, resulting on a false "ischemic penumbra" of the other lobe. Thus, it's vital not to focus only on the predicting color maps.

Also, abnormally increased regional vascularity instead of artery stenosis in CTA suggests SE as alternative diagnosis.Finally, patient's posterior seizure and electroencephalographic findings confirmed the diagnosis of SE.

CONCLUSION

Epileptic status is a condition that could mimic an ischemic stroke. ACT and PTC findings are crucial to distinguish this entity and prevent misguided treatments. Paying attention to absolute values of PTC is determining to avoid misdiagnosis.

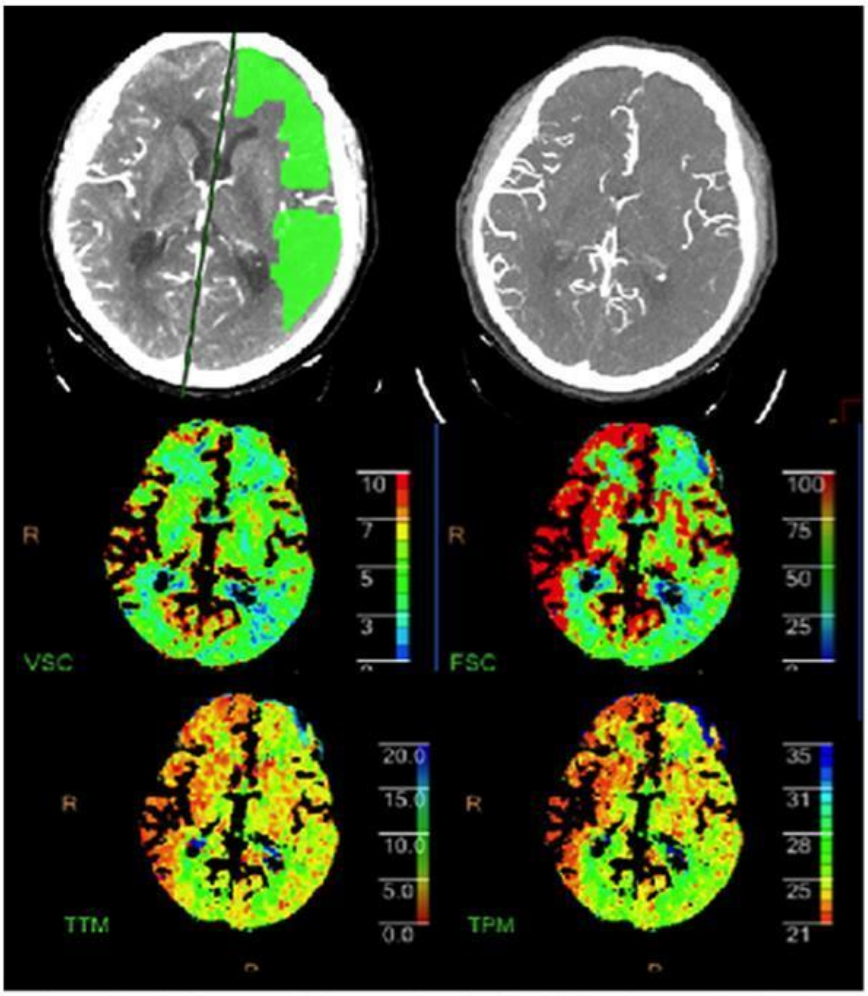

Figure1 (top left). PCT prediction map showing false "ischemic penumbra" in the left lobe. Figure2 (top right). Increased right lobe vascularity in CTA. Figure3 (bottom). PCT colour maps revealing decreased MTT and increased CBF in the right lobe.

BIBLIOGRAPHY

- Sotoudeh H. Status Epilepticus, Hemispheric Confusion, a CT Perfusion Pitfall in "Code Stroke" Patients: A Case Report. Iran J Radiol, 2019; 16: 1.

- Guerrero W, Dababneh H, Eisenschenk S. The role of perfusion CT in identifying stroke mimics in the emergency room: a case of status epilepticus presenting with perfusion CT alterations. Int J Emerg Med, 2012; 5: 4.